

# Ultrasound diagnosis of ulnar nerve dislocation and snapping triceps syndrome

**V B Gupta, MBBS, DNB**  
**K B Patankar, MD, DMRD**  
**F Paranjpe, MD**  
**J Patil, MD, DNB**

Department of Radiology, Apple Hospital, Kolhapur, Maharashtra, India

Corresponding author: V Gupta (vivekforever@lycos.com)

Dislocation of the ulnar nerve with snapping triceps syndrome has been implicated as a cause of cubital tunnel syndrome. Patients with this condition may clinically present with a snapping sensation at the elbow upon flexion along with ulnar neuropathic symptoms. Though demonstration of this condition is possible by static MRI images, ultrasound can be used as a more accessible and inexpensive modality for attaining diagnosis. This pictorial essay emphasises the technique, findings and role of dynamic ultrasound in the diagnosis of this entity.

*S Afr J Rad* 2012;16(2):65-67.

## Introduction

The preferred modality for imaging of the musculoskeletal system for suspected nerve entrapment is magnetic resonance imaging (MRI). Alternatively, high-resolution ultrasound (US) can be an inexpensive and more accessible modality. One of the assets of US in musculoskeletal imaging is its ability to image parts in dynamic motion, which may not be feasible for conventional MRI or CT. This essay emphasises the role of US in the diagnosis of ulnar nerve dislocation and snapping triceps syndrome and describes the preferred technique, imaging findings and dynamic monitoring by US. The essay highlights the need for awareness of this entity when dealing with medial elbow pain and/or ulnar neuropathy. Though the condition of ulnar nerve dislocation itself is not uncommon, the fact that it can be associated with triceps snapping is often overlooked, and the combination of ulnar nerve dislocation with triceps snapping syndrome has been implicated as one of the causes of cubital tunnel syndrome. Once diagnosed, options of conservative as well as surgical management of the condition are available.

## Clinical presentation

A 35-year-old male manual labourer presented with pain in the left elbow region. He complained of a characteristic snapping sensation in the medial aspect of his elbow on flexion. The pain was along the ulnar nerve distribution and was often associated with tingling and numbness. The symptoms were of increasing severity over a 6-month period. There was no history of fever. His past history was unremarkable. On local examination, there was no visible swelling at the elbow. His basic laboratory investigations were normal. Plain films were normal. An US of the left elbow was advised.

## Ultrasound technique

At sonography, the position of the ulnar nerve was noted with respect to the medial epicondyle. The patient was examined in the seated position with both elbows comfortably resting on a cushion placed on his lap. US of the left elbow was performed at the level of the cubital tunnel; this was achieved by placing the transducer over the medial epicondyle at one end and over the head of the olecranon at the other end of the transducer. A high-frequency (8.5 MHz) linear transducer was used. The elbow at the level of the cubital tunnel was examined initially in extension and then in flexion. The patient was made to externally rotate his shoulder for optimal visualisation of the cubital tunnel. Dynamic US of the tunnel was performed while flexing the elbow. Comparison was made with the asymptomatic right elbow. Care should be taken not to exert too much pressure with the probe as this will prevent dislocation.<sup>1</sup>

## Findings

With the arm in extension, the ulnar nerve was noted in the cubital tunnel and the adjacent triceps muscle was in the expected normal position posterior to the apex of the medial epicondyle on extension (Figs 1 and 2). The site of the common origin of the flexor muscles of the forearm was identified at the apex of the medial epicondyle. There

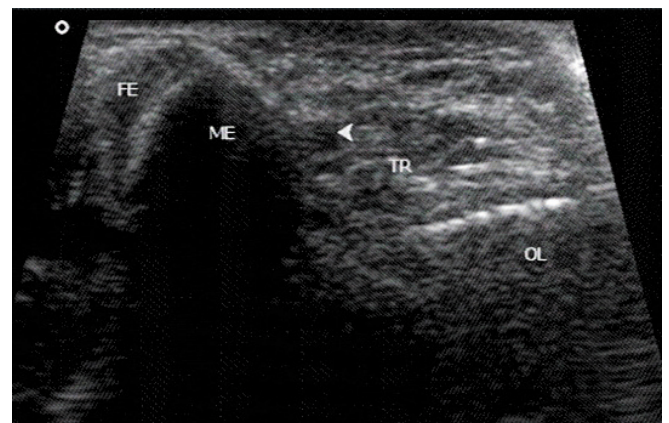


Fig. 1. The asymptomatic right elbow at the level of the cubital tunnel. The elbow is in extension. The ulnar nerve (arrowhead) and the medial head of the triceps muscle (TR) are in the cubital tunnel posterior to the apex of the medial epicondyle (ME). The common origin of the flexor muscles (FE) of the forearm is visualised at the apex of the medial epicondyle. One end of the transducer is at the medial epicondyle and the other at the head of the olecranon (OL).

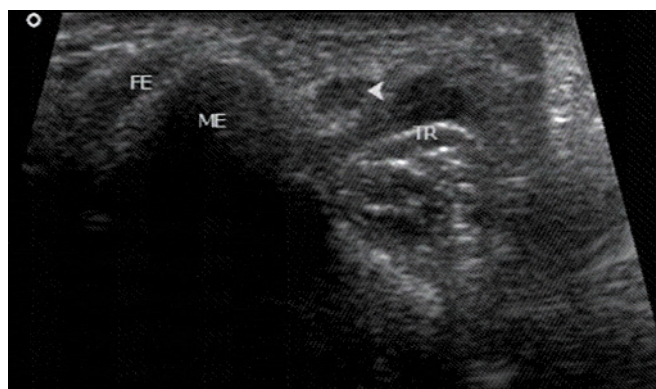


Fig. 2. The symptomatic left elbow at the level of the cubital tunnel in extension. The ulnar nerve (arrowhead) and the medial head of triceps (TR) are in the cubital tunnel posterior to the medial epicondyle (ME) similarly to the anatomy of the extended right elbow. Note the round contour of the cross-section of the ulnar nerve.

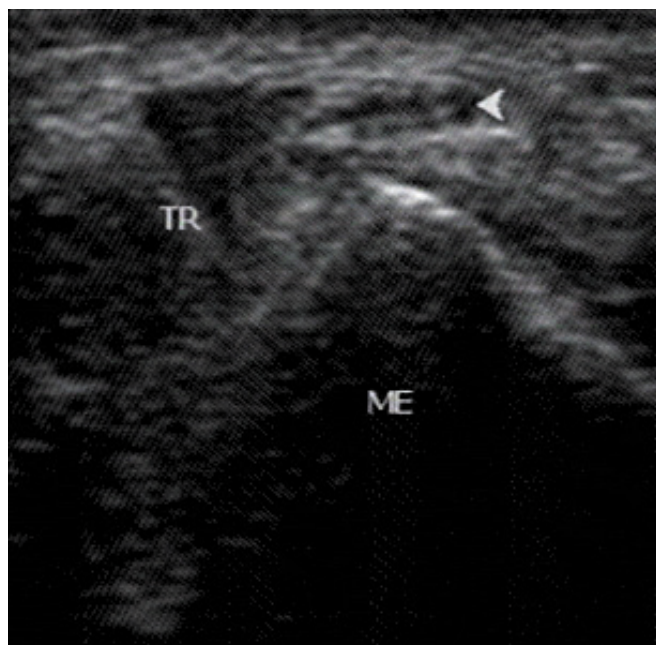


Fig. 3. The symptomatic left elbow at the level of the cubital tunnel in mid-flexion. The ulnar nerve (arrowhead) has moved over the medial epicondyle (ME). Note the flattening of the contour of the ulnar nerve. In addition, the medial head of the triceps (TR) has moved towards the medial epicondyle.

was no significant difference in the cross-sectional diameter of the ulnar nerves in comparison on extension measured at the level of the medial epicondyle. In the symptomatic left elbow, following flexion, the ulnar nerve dislocated over the medial epicondyle and lay anteromedially. The triceps muscle was also noted to dislocate and move over the medial epicondyle (Figs 3 and 4). The ulnar nerve and adjacent triceps remained stable in the asymptomatic right side (Fig. 5). There was separation of the ulnar nerve from the triceps while dislocating over the apex of the medial epicondyle. This phenomenon was well demonstrated using dynamic extension followed by flexion with the transducer held firmly with respect to the medial epicondyle continuously monitoring the movement in the cubital tunnel. The moment of dislocation of the ulnar

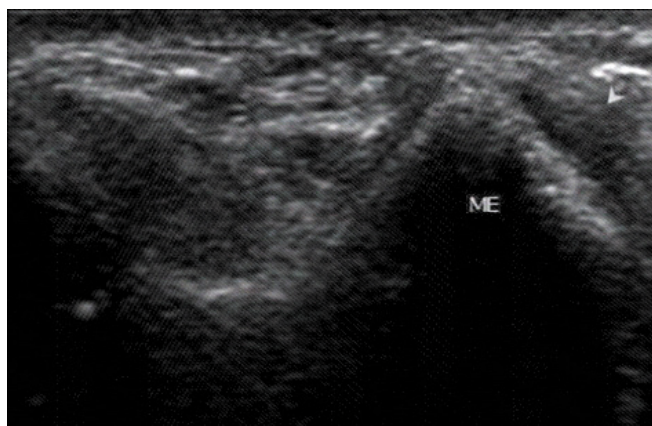


Fig. 4. At full flexion, the ulnar nerve along with the medial head of the triceps have dislocated (shown by the arrowhead) over the medial epicondyle (ME). The dislocation was perceived as a snapping sensation felt through the transducer.

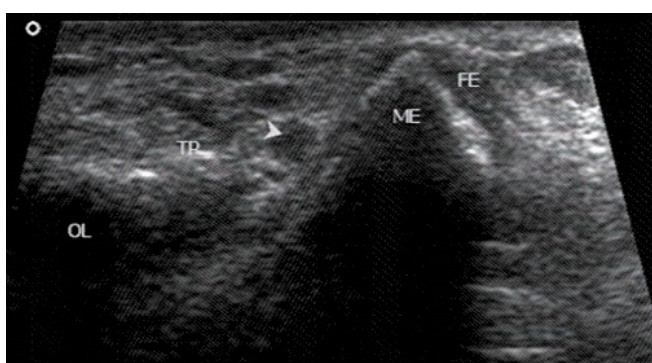


Fig. 5. The asymptomatic right elbow at the level of the cubital tunnel is depicted at full flexion following continuous dynamic monitoring by keeping the transducer fixed over the medial epicondyle (ME) during flexion. The ulnar nerve (arrowhead) and medial head of triceps (TR) remain in the cubital tunnel posterior to the medial epicondyle with no evidence of dislocation.

nerve and triceps over the medial epicondyle that be felt by the patient as a snapping sensation was also noted by the observer. After flexion, the cross-sectional appearance of the dislocated ulnar nerve over the medial epicondyle appeared elongated and obtained a flattened shape instead of its normal rounded appearance in the cubital tunnel (Fig. 4). After extension, the ulnar nerve and triceps were noted to revert back to their respective normal positions and morphology in the cubital tunnel.

The US findings were consistent with ulnar nerve dislocation and associated triceps snapping syndrome. Nerve conduction studies were positive for ulnar neuropathy at the elbow.

The patient was initially managed conservatively on an analgesic regime but did not show significant clinical improvement, and subsequently underwent surgery. Intra-operatively, on passive flexion and extension of the elbow, the ulnar nerve as well as the medial head of the triceps were noted to dislocate over the medial epicondyle, confirming the diagnosis. The ulnar nerve was transpositioned anteriorly and the medial head of the triceps was transpositioned laterally by the orthopaedic surgeon. On a post-surgery follow-up at 6 months, the patient reported significant relief from the symptoms.

## Discussion

Cubital tunnel syndrome is a concise term for conditions that result in strain on the ulnar nerve at the elbow. Patients with this condition typically complain of pain and tingling numbness in the distribution of the ulnar nerve, exaggerated on flexion of the elbow.<sup>2</sup> One of the possible causes for cubital tunnel syndrome is ulnar nerve dislocation, which may be associated with triceps snapping syndrome. In this condition, the ulnar nerve dislocates over the medial epicondyle following flexion of the elbow which may or may not be accompanied by triceps dislocation. As the elbow moves from extension to flexion, the distance between the medial epicondyle and the olecranon increases by 5 mm for every 45° of elbow flexion. The cubital tunnel's loss in height with flexion results in a 55% volume decrease in the canal, which doubles the mean ulnar intraneural pressure.<sup>3,4</sup> Subluxation of the nerve is common, and not every individual with this condition is symptomatic. Friction generated with repeated subluxations may cause inflammation within the nerve and, in the subluxed position, the nerve may be more susceptible to inadvertent trauma.<sup>5,6</sup>

Congenital absence of the cubital tunnel retinaculum, a fibrous band extending from the olecranon process to the medial epicondyle and forming roof of the cubital tunnel, is thought to be one of the causes of ulnar nerve dislocation with triceps snapping.<sup>7</sup> Other possibilities include bodybuilding, post-trauma effects, congenital accessory triceps tendon and abnormal medial triceps.<sup>8</sup>

Dynamic US can help to demonstrate abnormal dislocation of the ulnar nerve, with and without snapping triceps syndrome through continual visualisation of the ulnar nerve and triceps muscle in active elbow flexion and extension.<sup>1</sup> Knowledge of this condition and the relevant anatomy is essential for diagnosis and for musculoskeletal US in general. The condition can also be demonstrated through MRI and CT,<sup>9</sup> which requires imaging the limb in static extension and flexion to diagnose the dislocation. However US is a cost-effective modality which has the superior advantage of demonstrating the condition dynamically. Additionally, the snapping sensation on dislocation can be actively appreciated on US by the examiner.

The technique for an US diagnosis of ulnar nerve dislocation and triceps snapping requires identification of the apex of the medial epicondyle as a landmark.<sup>1</sup> On extension, the ulnar nerve is located

posterior to the epicondyle which dislocates over it on flexion, reverting to its original position on extension. If the medial head of the triceps also dislocates over the medial epicondyle, triceps snapping is also associated, which may be felt as two snaps: the first when the ulnar nerve dislocates, followed by a second snap upon triceps dislocation. If the medial head of the triceps does not dislocate, isolated dislocation of the ulnar nerve should be considered. US findings suggest that dislocation is diagnosed conclusively on flexion. As appreciated in this case, it has been shown that the ulnar nerve flattens during elbow flexion, and this flattening is most marked with ulnar nerve subluxation.<sup>10</sup>

Treatment for this condition depends on symptom severity. For milder cases, conservative treatment including physiotherapy and avoiding activities involving repeated flexion and extension may suffice. Patients with persistent or severe symptoms may require surgery such as lateral repositioning, medial epicondylectomy or anterior transposition of the ulnar nerve.<sup>6,9</sup>

**Acknowledgements.** We thank Dr Ajit Patil, the orthopaedic surgeon managing this case, for his co-operation; Miss Geeta Awate, General Manager, Apple Hospital, for her keen interest in research projects at the institute; Dr V Degaonkar for his invaluable guidance; and Mr Yuvraj Shinde for his contribution in preparing the manuscript and images.

1. Jacobson JA, Jebson PJ, Jeffers AW, Fessell DP, Hayes CW. Ulnar nerve dislocation and snapping triceps syndrome: Diagnosis with dynamic sonography - report of three cases. *Radiology* 2001;220(3):601-605.
2. Cubital Tunnel Syndrome, Information for Public And Patients. Rosemont, IL: American Society for Surgery of the Hand, 2011.
3. Watchmaker GP, Lee G, Mackinnon SE. Intraneural topography of the ulnar nerve in the cubital tunnel facilitates anterior transposition. *J Hand Surg [Am]* 1994;19(6):915-922.
4. Pechan J, Julis I. The pressure measurement in the ulnar nerve. A contribution to the pathophysiology of the cubital tunnel syndrome. *J Biomech* 1975;8(1):75-79.
5. Childress HM. Recurrent ulnar-nerve dislocation at the elbow. *Clin Orthop* 1975;108:168-173.
6. Verheyden JR, Palmer AK. Cubital tunnel syndrome. *Medscape*, June 2011. <http://emedicine.medscape.com/article/1231663-overview#a0104> (accessed 6 January 2012).
7. O'Driscoll SW, Horii E, Carmichael SW, Morrey BF. The cubital tunnel and ulnar neuropathy. *J Bone Joint Surg Br* 1991;73:613-617.
8. Spinner RJ, Goldner RO. Snapping of the medial head of the triceps and recurrent dislocation of the ulnar nerve. *J Bone Joint Surg Am* 1998;80:239-247.
9. Spinner RJ, Hayden FR, Hipps CT, Goldner RD. Imaging of snapping triceps. *Am J Roentgenol* 1996;167:1550-1551.
10. Okamoto M, Abe M, Shirai H, Ueda N. Morphology and dynamics of the ulnar nerve in the cubital tunnel: observation by ultrasonography. *J Hand Surg [Br]* 2000;25:85-89.