

Abdominal imaging

S K Misser, S Beningfield, P Scholtz

Lake Smit and Partners, Durban
S K Misser, MB ChB, FC Rad (D) SA

Department of Radiology, University of Cape Town
S Beningfield, MB ChB, FFRad (D) SA
P Scholtz, MB ChB, FC Rad (D) SA

Corresponding author: S Misser (misser@lakesmit.co.za)

Presentation

A 40-year-old man presented with acute onset of severe vomiting. From the images provided, describe the relevant findings and provide the most appropriate clinical diagnosis. Please submit your response to Dr Misser at misser@lakesmit.co.za not later than 11 January 2013. The winning respondent will receive a R1 000 award from the RSSA. A

detailed diagnosis and discussion will be presented in the next issue of the SAJR.

S Afr J Rad 2012;16(4):152. DOI:10.7196/SAJR.795

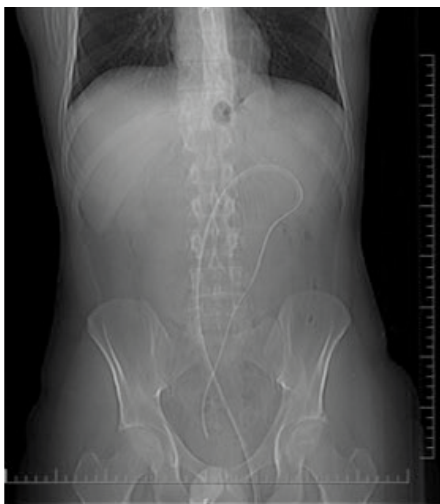

Fig. 1. Plain abdominal radiograph.

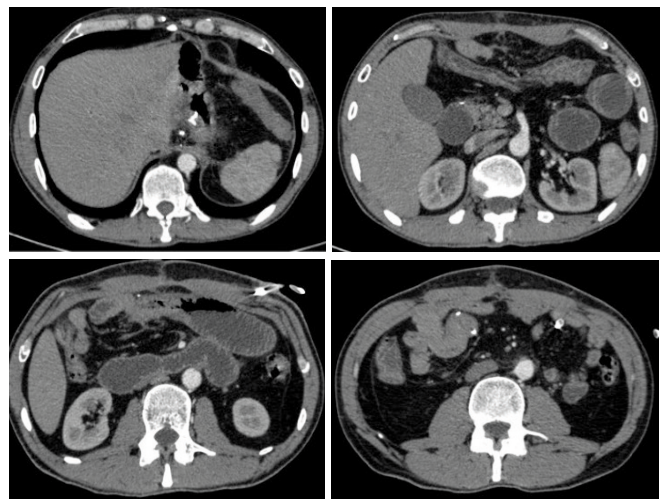


Fig. 2. Selected axial post-contrast CT images of the abdomen.