

An unusual case of intrahepatic portosystemic venous shunt

P Naidoo, MB BCh, FCRad Diag (SA); **N Maharaj**, MB ChB, FCRad Diag (SA);
V Naidu, MB ChB, FCRad Diag (SA); **J Maharajh**, MB ChB, FFRad (D) SA, MMed Rad (D)

Department of Diagnostic Radiology, Nelson R Mandela School of Medicine, University of KwaZulu-Natal and King Edward VIII Hospital, Durban, South Africa

Corresponding author: P Naidoo (pumersh@hotmail.com)

Intrahepatic portosystemic venous shunts are rare vascular anomalies that may be detected in asymptomatic patients, given the recent advances in radiological imaging techniques. Accurate shunt evaluation and classification can be performed with ultrasound and multi-detector computed tomography. We report an unusual case of an intrahepatic portosystemic venous shunt with an incidental finding of neurofibromata.

S Afr J Rad 2013;17(2):57-58. DOI:10.7196/SAJR.761

A 29-year-old woman with known hypertension and schizophrenia presented with vague abdominal pain. Biochemistry revealed increased gamma-glutamyl transferase (GGT) and alkaline phosphatase (ALP) levels. Ultrasound detected a plexus of vascular, serpiginous structures in the porta hepatis anterior to the portal vein, and a provisional diagnosis of hepatic vascular malformation was considered. Computed tomography (CT) demonstrated a conglomerate of dilated vessels in the region of the porta hepatis with an intrahepatic portosystemic venous shunt, also known as a portal hepatic venous shunt, between the right portal vein and the middle hepatic vein (Figs 1a and 1b). In addition, numerous well-defined low-density non-enhancing soft-tissue masses were noted in the pelvis. Enlarged, scalloped anterior sacral foramina were observed consistent with neurofibromata (Fig. 1c).

Discussion

Portal to systemic venous communications are classified as intrahepatic or extrahepatic.^[1] Intrahepatic shunts are less common and occur

between intrahepatic portal veins and systemic veins.^[2] Extrahepatic communications may be present in patients with portal hypertension due to cirrhosis and other causes, with the shunt through collateral vessels.

The pathogenesis of intrahepatic non-tumorous portosystemic shunts is controversial.^[1] Some authors believe that the cause is congenital, owing to persistent vitelline veins and the sinus venosus.^[1-3] Others believe them to be post-traumatic, iatrogenic or as a result of portal hypertension with varices caused by liver disease or infections.^[1]

Intrahepatic portosystemic shunts are usually discovered incidentally, or on presentation of complications such as hepatic encephalopathy. Other complications include liver failure, cirrhosis, pulmonary arterial hypertension and metabolic abnormalities such as hypergalactosaemia and hyperammonaemia.^[2,4]

Park and other workers^[1,2] have characterised intra-hepatic portosystemic shunts into 4 morphological types:

- single large shunt that connects the right portal vein to the inferior vena cava (IVC) (most common)

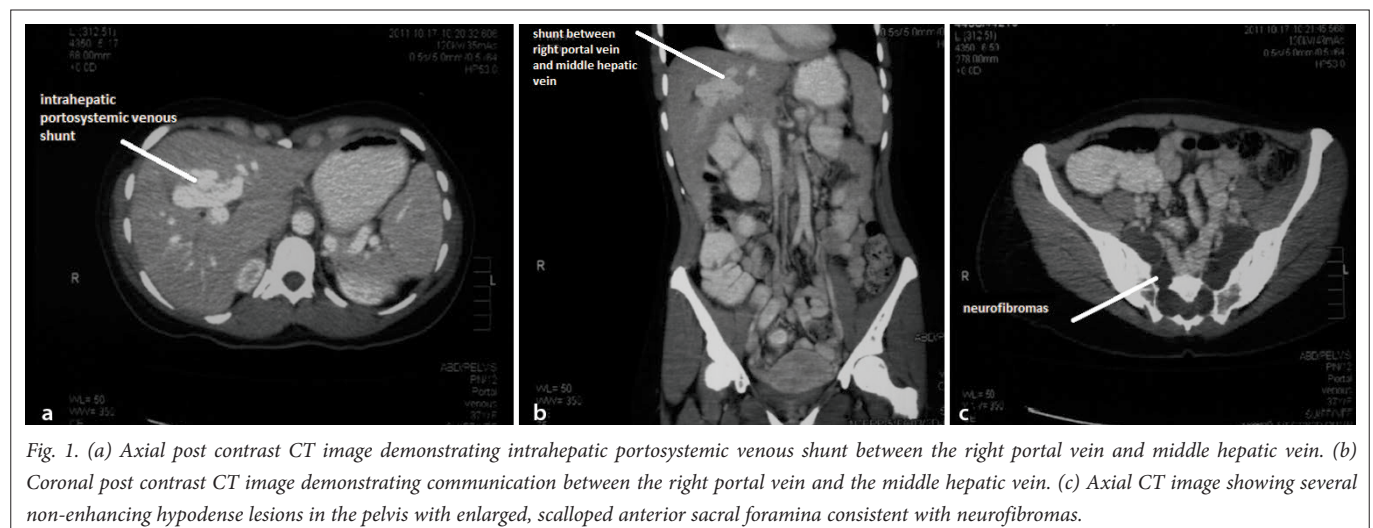


Fig. 1. (a) Axial post contrast CT image demonstrating intrahepatic portosystemic venous shunt between the right portal vein and middle hepatic vein. (b) Coronal post contrast CT image demonstrating communication between the right portal vein and the middle hepatic vein. (c) Axial CT image showing several non-enhancing hypodense lesions in the pelvis with enlarged, scalloped anterior sacral foramina consistent with neurofibromas.

- localised peripheral shunt in which one or more communications are found in a single hepatic segment
- portosystemic shunt through a portal vein 'aneurysm'
- diffuse and multiple communications between peripheral portal and hepatic veins in several segments.

Ultrasound of the abdomen usually reveals abnormal cystic or tubular, anechoic, serpiginous vascular structures communicating between portal venous structures and the systemic circulation.^[2] Doppler ultrasound can confirm the vascular nature of the structures and calculate a shunt ratio (total blood flow volume in the shunt divided by the blood flow in the portal vein). It is thought that a shunt ratio greater than 60% should be corrected owing to the risk of complications.^[2]

On contrast-enhanced CT, a rounded mass with strong homogenous enhancement is demonstrated, with abnormal communication between a portal vein branch and hepatic vein or IVC.^[1] MRI would provide a similar appearance to CT, with the added advantage of MR venography. Nuclear medicine can also be used to calculate the shunt ratio by portal scintigraphy following submucosal rectal injection of iodine-123 iodoamphetamine.^[2] Minimally symptomatic patients, as in our case report, may reasonably be followed up to detect hepatic encephalopathy and hepatocellular carcinoma.^[4]

Treatment may be necessary in symptomatic patients.^[1] Options include transcatheter embolisation or surgical correction with liver

transplantation as a last resort.^[2] Neurofibromatosis type 1 (NF1) has a well-known association with vascular anomalies such as stenoses and aneurysms. Oktenli *et al.* recorded a specific association between NF1 and intrahepatic portosystemic shunts.^[5]

Conclusion

Intrahepatic portosystemic shunts are rare vascular abnormalities that may incidentally be detected in asymptomatic patients. Accurate evaluation of the shunt can be performed with modern advanced radiological imaging techniques. Considering the many documented vascular anomalies associated with NF1, this case report supports the association between NF1 and congenital intrahepatic portosystemic venous shunts.^[5]

1. Tsitouridis I, Sotiriadis C, Michaelides M, et al. Intrahepatic portosystemic venous shunts: Radiological evaluation. *Diagnostic and Interventional Radiology* 2009;15:182-187.
2. Gallego C, Miralles M, Marin C, et al. Congenital hepatic shunts. *Radiographics* 2004;24:755-772. [<http://dx.doi.org/10.1148/rg.243035046>]
3. Lane MJ, Jeffrey RB, Katz DS. Spontaneous intrahepatic vascular shunts. *AJR* 2000;174(1):125-131.
4. Konstas AA, Digumarthy SR, Avery LL, et al. Congenital portosystemic shunts: Imaging findings and clinical presentations in 11 patients. *EJR* 2011;80(2):175-181. [<http://dx.doi.org/10.1016/j.ejrad.2009.12.031>]
5. Oktenli CO, Gul D, Deveci MS, et al. Unusual features in a patient with neurofibromatosis type 1: Multiple subcutaneous lipomas, a juvenile polyp in ascending colon, congenital intrahepatic portosystemic venous shunt, and horseshoe kidney. *Am J Med Genet* 2004;127A:298-301. [<http://dx.doi.org/10.1002/ajmg.a.30008>]