

# Intermittent intestinal obstruction due to chronic colo-colic intussusception

**WCG Peh**

MBBS, DMRD, FRCR, FAMS  
Associate Professor

**W Cheng\***

MBBS, FRCSE, FRCSG, FRACS  
Assistant Professor

Departments of Diagnostic Radiology  
and \*Surgery (Paediatric Surgery Division),  
The University of Hong Kong,  
Queen Mary Hospital, Hong Kong

## Abstract

A two year old boy presented with a two month history of intermittent bloody diarrhoea, and associated intermittent colicky abdominal pain and weight loss. A small mass was palpable over the left abdomen. Abdominal radiograph showed colonic obstruction and barium enema revealed colo-colic intussusception. At laparotomy, the intussusception had reduced spontaneously and was found to be caused by a benign juvenile polyp. The clinical and imaging

features, and management of the chronic form of intussusception are discussed.

## Case report

A two year old Chinese boy presented with a two month history of intermittent diarrhoea. Mucus and blood was occasionally noted in the stools. There was associated intermittent colicky abdominal pain and weight loss of 2 kg. The child enjoyed previous good health. Prior to admission, he was seen by a private practitioner and had been treated with antibiotics without improvement. On examination, a small firm mass was palpable over the left upper abdomen. Ultrasound scan did not however show any abnormality. Stool cultures for various micro-organisms, and blood serology and cultures, were all negative.

Abdominal radiograph (Figure 1), done during the next severe episode

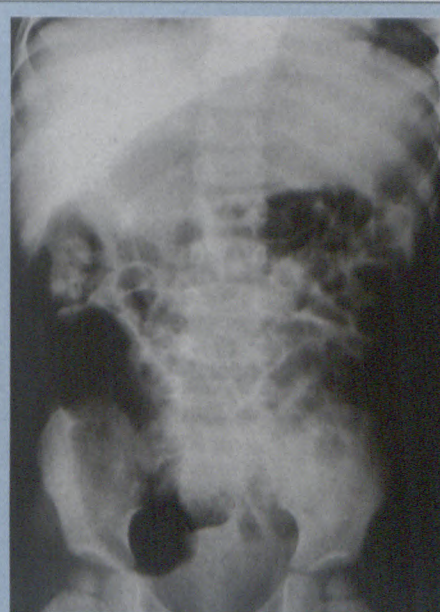


Figure 1: Supine abdominal radiograph shows dilatation of the small bowel and the proximal hemi-colon.



**(multispecialty)**

# Ready for everything.

## Announcing ImagePoint, from Hewlett-Packard®

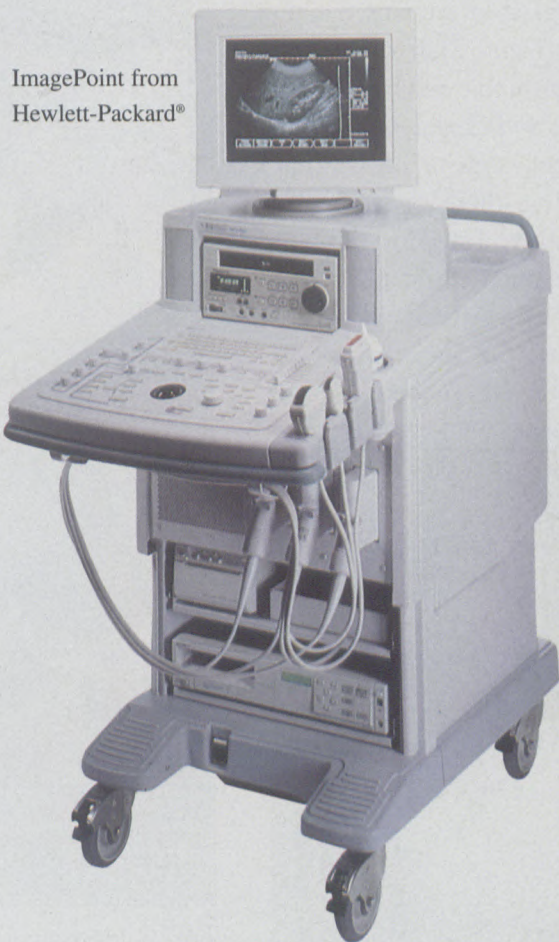

The innovative, ergonomic keyboard is designed for comfort and ease of use.


**I**magePoint is the multispecialty, high-performance digital ultrasound system that covers a wide range of ultrasound examinations. Whatever your needs – abdominal, vascular, OB/GYN, small parts, cardiac, paediatric – ImagePoint brings Hewlett-Packard's tradition of innovation and performance to ultrasound. And ImagePoint comes complete with all these applications, without compromise in image quality.

ImagePoint's exceptional digital imaging provides outstanding resolution. Its simple, ergonomic design is comfortable and efficient. Global, comprehensive training and support are available when you need them. And ImagePoint is affordable to buy and cost-effective to operate. It's easy to learn, easy to use, easy to upgrade and easy to move.


In short, **easy to own.**



ImagePoint from Hewlett-Packard®



*HiPerformance  
Systems*

 **HEWLETT  
PACKARD**

For more information please contact Lynnette Lewis at HiPerformance Systems, sole authorised distributor of Hewlett-Packard medical equipment, at (011) 806-1229 or Glen Strike in Durban (031) 207-2073 or Diane Romburgh in Cape Town (021) 658-6202

# Intermittent intestinal obstruction due to chronic colo-colic intussusception

from page 19

of abdominal pain, showed dilated loops of gas-filled small bowel, as well as distention of the ascending and transverse colon. An urgent barium enema was performed on suspicion of colonic obstruction in the region of the splenic flexure. Complete obstruction at the proximal descending colon was confirmed, with a concave defect at the head of the barium column and a classic "coiled-spring" appearance, typical of intussusception, beyond that (Figure 2). Combination of plain radiographic and barium enema findings were highly suggestive of the colo-colic type of intussusception. In addition, there was a polypoidal filling defect located just distal to the intussusception site on the barium study (Figure 2). Attempted hydrostatic reduction of intussusception using barium was unsuccessful.

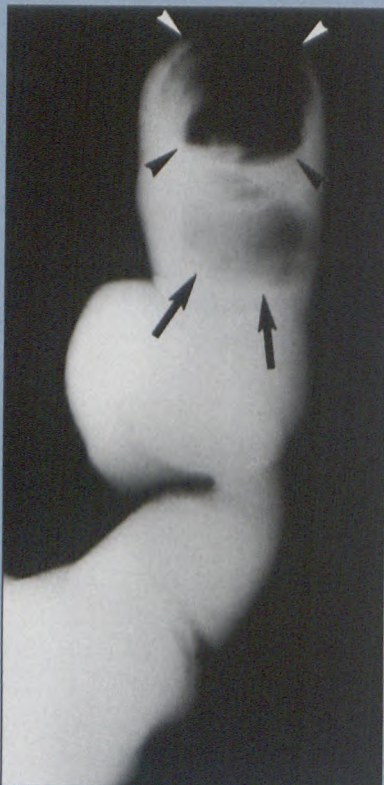


Figure 2: Barium enema coned to show the descending colon and proximal sigmoid colon shows the "coiled-spring" appearance of intussusception (arrowheads), as well as a polypoidal filling defect (arrows).

Laparotomy was performed later the same day. At surgery however, the colo-colic intussusception was found to have reduced spontaneously. A mass was palpable within the proximal descending colon and colotomy revealed a 3.5 x 2.5 x 1.7 cm polyp (Figures 3a and b), corresponding in

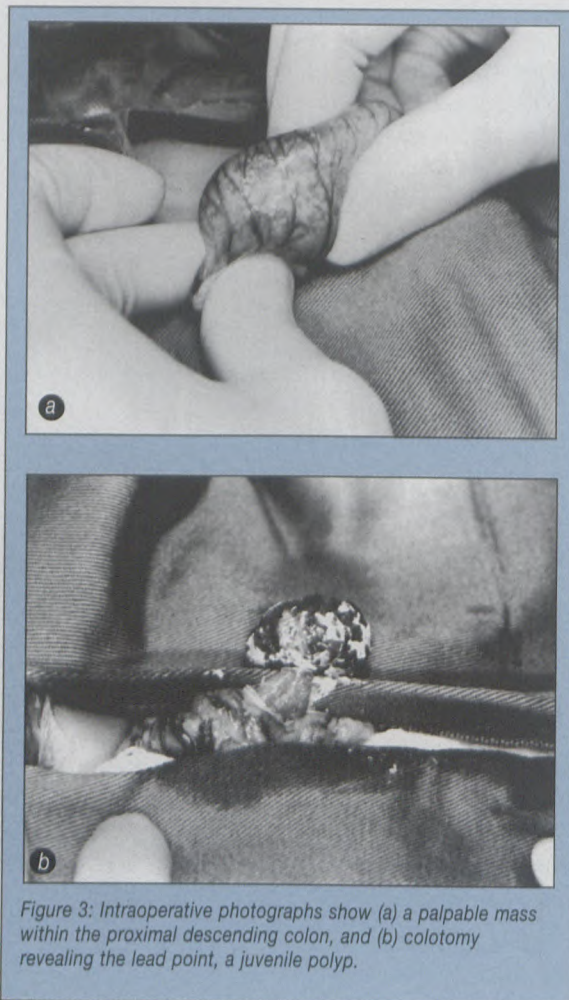


Figure 3: Intraoperative photographs show (a) a palpable mass within the proximal descending colon, and (b) colotomy revealing the lead point, a juvenile polyp.

site to the polypoidal filling defect seen on barium enema. Histopathology of the excised specimen showed features of a benign juvenile polyp. The patient recovered uneventfully and has remained well to date.

## Discussion

Intestinal intussusception is a common surgical emergency in children, requiring urgent diagnosis and treatment. Acute intussusception

is usually considered early in the differential diagnosis of a young child presenting with a short history of abdominal pain and vomiting. Chronic intestinal intussusception of greater than two weeks duration is uncommon, occurring in 6.5% of patients in one large series.<sup>1</sup> Chronic intussusception behaves differently from the acute form in that abdominal pain and vomiting are less severe, with diarrhoea and weight loss being recognized features. Chronic intussusception may even rarely present as failure to thrive. Except for the typical intermittent colicky abdominal pain, symptoms of chronic intussusception are generally rather non-specific.<sup>2-4</sup> Chronic intussusception tends to be found in older children and it has been suggested that at an older age, the anatomy is such that intussusception occurs without significant impairment of the blood supply.<sup>1</sup>

Ultrasound is now regarded as an accurate method to diagnose intussusception, offering the advantages of being quick, simple, non-invasive and radiation-free. It has been recommended that contrast enema should be reserved for ultrasonically-equivocal cases or for therapeutic reduction.<sup>5</sup> Spontaneous reduction of intussusception has been reported to occur.<sup>6,7</sup> On retrospect, the clinical picture of this patient fitted that of a chronic, intermittent-occurring and spontaneously-reducing intussusception. At the

to page 23

## Intermittent intestinal obstruction due to chronic colo-colic intussusception

from page 22

time of ultrasound and at surgery, the intussusceptum was not identified, while in-between, it produced the characteristic barium enema appearances of intussusception.

Colo-colic intussusception is the least frequently encountered type of intussusception, while the ileo-colic type is by far the commonest form.<sup>8</sup> Although detection of lead points using ultrasound has been reported,<sup>9</sup> the site of the polyp within a gas- and faecal-filled colon and absence of the spontaneously-reduced intussusceptum probably made ultrasonic assessment difficult in this patient. Causative lead points are not detected in the majority of intussusceptions, being reported in only 2.5-10% of cases.<sup>10,11</sup>

The presence of barium interposed between the intussusceptum and intussusciptens, the so-called "dissection sign", could have contributed to failure of hydrostatic reduction in this patient. The "dissection sign" causes

concentric compression of the intussusceptum and hence a decrease in the reductive force, due to fluid dynamics of the dissected barium. There is evidence that this sign may be a reliable predictor of failure of hydrostatic reduction.<sup>12</sup> In any case, even successful reduction of an intussusception does not exclude a lead point. Careful review of all imaging studies and meticulous examination during laparotomy should be carried out to diagnose lead points in order that they may be adequately treated. As chronic intussusception is frequently associated with a predisposing lesion and a low success rate of hydrostatic reduction, early surgical intervention is recommended for this form of intussusception.<sup>4</sup>

### References

1. Reijnen JAM, Festen C, Joosten HJM. Chronic intussusception in children. *Br J Surg* 1989;76:815-816.
2. Page AC, Price JF, Salisbury JR, Howard ER, Karani J. Chronic intussusception. *Arch Dis Child* 1990;65:134-135.

3. Watson NA, Bissett RAL. Intussusception - a cause of chronic abdominal symptoms and weight loss. *Clin Radiol* 1994;64:723-726.
4. Rees BI, Lari J. Chronic intussusception in children. *Br J Surg* 1976;63:33-35.
5. Shanbhogue RLK, Hussain SM, Meradji M, Robben SGF, Vernooij JEM, Molenaar JC. Ultrasonography is accurate enough for the diagnosis of intussusception. *J Pediatr Surg* 1994;29:324-328.
6. Morrison SL, Stork E. Documentation of spontaneous reduction of childhood intussusception by ultrasound. *Pediatr Radiol* 1990;20:358-359.
7. Swischuk LE, John SD, Swischuk PN. Spontaneous reduction of intussusception: verification with ultrasound. *Radiology* 1994;192:269-271.
8. Bissett GS III, Kirks DR. Intussusception in infants and children: diagnosis and therapy. *Radiology* 1988;168:141-145.
9. Lam AJ, Firman K. Ultrasound of intussusception with lead points. *Australas Radiol* 1991;35:343-345.
10. Ein SH. Leading points in childhood intussusception. *J Pediatr Surg* 1976;11:209-211.
11. Miller SF, Landes AB, Dautenhahn LW, et al. Intussusception: ability of fluoroscopic images obtained during air enemas to depict lead points and other abnormalities. *Radiology* 1995;197:493-496.
12. Fishman MC, Borden S, Cooper A. The dissection sign of nonreducible ileocolic intussusception. *AJR* 1984;143:5-8.

## The renal transplant score - a different way of evaluating renal transplant pathology

from page 18

2. Dubovsky EV, Russel CD, Erbas B. Radionuclide evaluation of renal transplants. *Seminars in Nuclear Medicine* 1995; 25: 49-59.
3. Nicoletti R. Evaluation of renal transplant perfusion by functional imaging. *Eur J Nucl Med* 1990; 16: 733-739.
4. Mizuiri S, Hayashi I, Takano M, Ban R, Ohara T, Susiki Y, Hasegawa A. Fractional mean transit time in transplanted kidneys studied by technetium-99m-DTPA: Comparison of clinical and biopsy findings. *J Nucl Med* 1994; 35: 84-89.
5. Ash J, De Souza M, Peters M, Wilmont D, Hansen D, Gilday D. Quantitative assessment of blood flow in Pediatric recipients of renal transplants. *J Nucl Med* 1990; 31: 580-585.
6. Dubovsky EV, Russel CD. Radionuclide evaluation of renal transplants. *Seminars in Nuclear Medicine* 1988; 18(3): 181-198.
7. Kittner CH, Esther G, Finck W, Bast R, Templin R, Wisse H, Brockmüller S. Der Trendverteilungs Quotient, ein neues Werkzeug zur Auswertung der Nierenperfusionsszintigrafie mit 99m-Tc DTPA nach Nieren Transplantation. *Nucl Med* 1993; 32: 37-41.
8. Lear JL, Raff U, Jain R, Horgen JG. Quantitative measurement of renal perfusion following transplant surgery. *J Nucl. Med.* 1988; 29: 1656-1661.
9. Smith SB, Wombolt DG. Histologic correlation of transplant rejection diagnosed by computer assisted sulphur colloid scan. *Urology* 1983; 21(2): 151-153.
10. Kim EE, Pjura G, Lowry P, Verani R, Sandler C, Flechner S, Kahan B. Cyclosporin - A nephrotoxicity and acute cellular rejection in renal transplant recipients: correlation between Radionuclide and Histologic findings. *Radiology* 1986; 159: 443-446.