

Endovascular foreign objects retrieved by interventional radiologists at Universitas Hospital

H F Potgieter

MB ChB

E Loggenberg

MMedRad (D)

*Department of Diagnostic Radiology
University of the Free State and
Universitas Hospital
Bloemfontein*

Abstract

During the past 4 years, 15 patients have undergone intravascular removal of foreign bodies — 9 central venous line fragments, 3 guidewires, 2 pacemaker leads and 1 misplaced embolisation coil. Ten foreign bodies (including 2 guidewires, 2 pacemaker leads and 6 central venous catheter fragments) were recovered from the big veins and right heart, 3 (central venous line fragments) from the pulmonary arterial system and 2 (an embolisation coil and a guidewire) from the arterial system. The percutaneous removal of foreign bodies is efficient with few complications. Surgery should only be considered for patients in whom removal attempts with endovascular interventional

techniques have failed.

Introduction

In the past, intravascular foreign bodies had to be removed surgically, but the percutaneous retrieval of intravascular foreign bodies has become a frequently used technique since it was first described 40 years ago,¹ largely replacing open surgical removal. Commonly encountered intravascular foreign bodies include fragments of central venous catheters (most common), knotted pulmonary artery (Swan Ganz) catheters, lost guidewires or guidewire fragments, misplaced embolisation coils and metallic stents. An estimated 0.1% of venous catheters suffer breakage² but no data are available for other types of intravascular objects.

The rate of serious complications caused by foreign body embolism is as high as 71%, with the mortality rate ranging from 24% to 60%.^{3,4} In the case of intravenous foreign objects, such as a fragment of a central venous catheter, it is important that the procedure be done as soon as possible. Attempts at removal from the venous

system prior to migration into the pulmonary circulation has the lowest morbidity and the highest chance of success (Figs 1a and 1b).⁵

Method

A vascular sheath big enough to allow removal of the foreign body in question must be used. Sometimes it is helpful to cut the sheath tip obliquely in order to increase the cross-sectional diameter of the opening allowing a bigger object to be pulled into

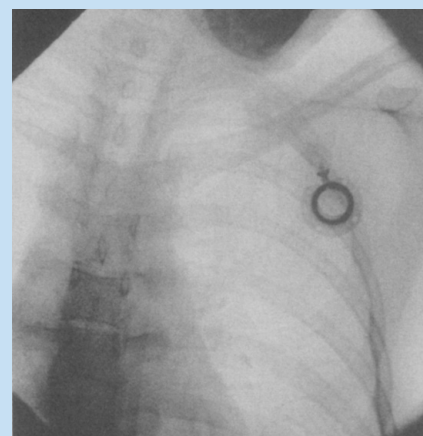


Fig. 1a. Infusoport without catheter.

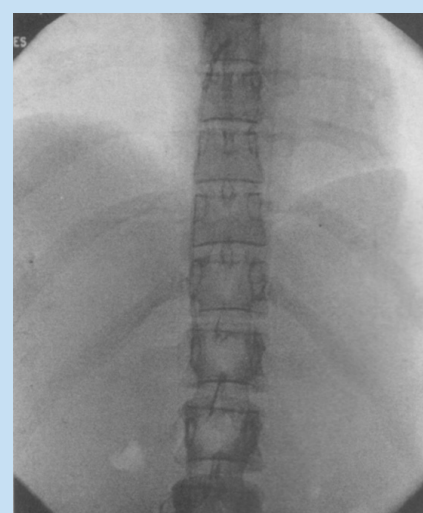

Fig. 1b. Lost central venous line in IVC and right atrium.

the sheath (Fig. 2).⁵ The most useful device in foreign body retrieval is the nitinol goose neck snare.⁶ Advantages of this device include the predefined loop diameter, the shape-memory properties of the nitinol, and the ability to develop a variable amount of force in the loop. Other devices that may be useful in this procedure include dormia-type baskets, self-made wire-snare (looped guidewire in a diagnostic catheter), biopsy forceps and purpose-designed fragment graspers.

As a standard procedure the Microvena goose neck snare (Fig. 3) was used with different guiding catheters in a Siemens Multistar interventional unit. The goose neck snare was manipulated over the free floating end of the lost object, which was snared and then removed through the sheath.

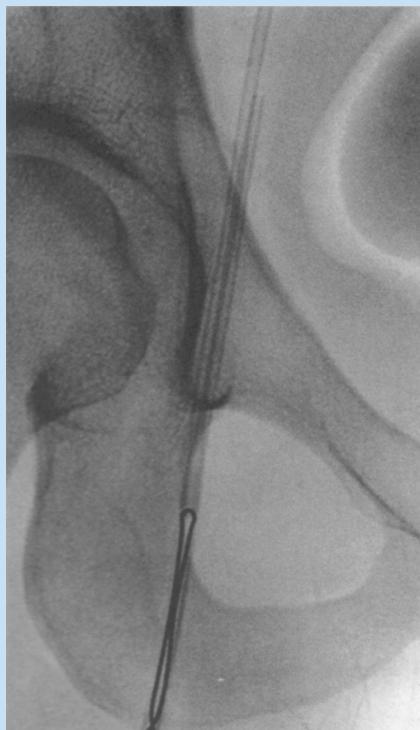


Fig. 2. Snared line fragment being recovered through sheath.




Fig. 3. Microvena goose neck snare.

Results

At Universitas Hospital radiology unit 15 patients have undergone intravascular removal of foreign bodies during the past 4 years. This included 9 central venous line fragments, 3 guidewires (Figs 4a and 4b), 2 pacemaker leads and 1 misplaced embolisation coil.

Ten foreign bodies (including 2 guidewires, 2 pacemaker leads and 6 central venous catheter fragments) were recovered from the big veins and right heart, 3 (central venous line fragments) from the pulmonary arterial system and 2 (an embolisation coil and a guidewire) from the arterial system.

All but 1 of the foreign bodies were removed successfully during the first attempt. The recovery of a 3 cm central line fragment from the pulmonary artery of 1 patient failed initially, but the second attempt 1 week later was successful. No serious adverse events were recorded during the procedures or immediately thereafter.

Discussion

Results continue to prove that percutaneous removal of foreign bodies is highly efficient (success rates more than 90% in most studies) with few complications. The added attraction of the procedure is that many serious-

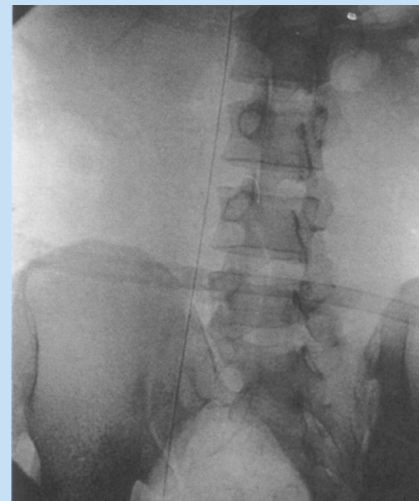


Fig. 4a. Lost guidewire in IVC.

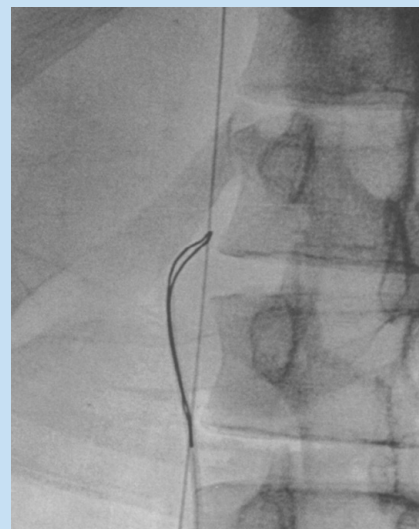


Fig. 4b. Guidewire in snare.

ly ill patients with iatrogenic foreign bodies do not have to be exposed to the increased surgical/anaesthetic risk. Owing to the associated complication risk, surgery should only be considered when removal attempts with endovascular interventional techniques have failed.

References

1. Thomas J, Sinclair-Smith B, Bloomfield D, Davachi A. Non-surgical retrieval of a broken segment of steel spring guide from the right

CASE REPORTS

- atrium and inferior vena cava. *Circulation* 1964; **30**: 106-108.
2. Burri C, Henkemeyer H, Passler HH. Catheter embolism. *Schweiz Med Wochenschr* 1971; **101**: 1575-1577.
 3. Fisher RG, Ferreyro R. Evaluation of current techniques for nonsurgical removal of intravascular iatrogenic foreign bodies. *Am J Roentgenol* 1978; **130**: 541-548.
 4. Richardson JD, Grover FL, Trinkle JK. Intravenous catheter emboli. Experience with twenty cases and collective review. *Am J Surg* 1974; **128**: 722-727.
 5. Allison DJ, Jackson JE. Vascular interventional techniques in the thorax. In: Grainger RG, Allison DJ, eds. *Grainger and Allison's Diagnostic Radiology: A Textbook of Medical Imaging*. 4th ed. London: Churchill Livingstone, 1997: 607 - 621.
 6. Cekirge S, Weiss JP, Foster RG, Neiman HL, McLean GK. Percutaneous retrieval of foreign bodies: experience with the nitinol goose neck snare. *J Vasc Interv Radiol* 1993; **4**: 805-810.
-